

See discussions, stats, and author profiles for this publication at: <https://www.researchgate.net/publication/313031017>

A study on core cut biopsy in bone lesions

Article · January 2017

DOI: 10.22271/ortho.2017.v3.i1a.03

CITATION

1

READS

12

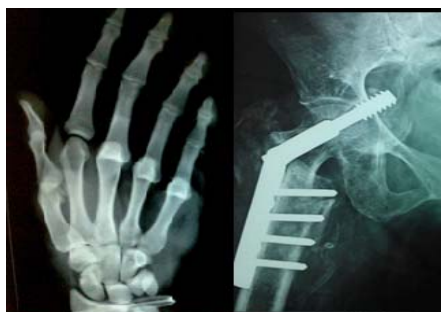8 authors, including:



[Nijith Ompedathil Govindan](#)

4 PUBLICATIONS 1 CITATION

SEE PROFILE



International Journal of Orthopaedics Sciences

ISSN: 2395-1958
IJOS 2017; 3(1): 09-13
© 2017 IJOS
www.orthopaper.com
Received: 03-11-2016
Accepted: 04-12-2016

Nijith O Govindan
MS-Ortho, Orthopedic Surgeon,
Department of Orthopedics,
Sunrise Hospital, Kakkanad,
Kochi, India

Jyothi Prasanth
DNB-Ortho, Junior Consultant,
Department of Orthopedics, Taluk
Hospital, Kuttyady, Calicut, India

Gopakumar TS
MS-Ortho, H.O.D of Department
of Orthopedics, MES Medical
College, Perinthalmanna,
Malappuram, India

Akhil R Nambiar
MD-Pathology, Assistant Surgeon,
PHC Narath, Kamur, India

Manjunath DS
MS-Ortho, Senior Consultant
Orthopaedics and Spine Surgeon,
Department of Orthopaedics,
Sunrise Hospital, Kakkanad,
Kochi, India

Prathap Kumar
FRCS (Tr & Orth), Consultant
Upper limb Surgeon, Department
of Orthopaedics, Sunrise Hospital,
Kakkanad, Kochi, India

Biju M Nair
FRCS, Senior Consultant in Joint
replacement & Lower limb
Arthroscopy, Department of
Orthopaedics, Sunrise Hospital,
Kakkanad, Kochi, India

Christeena Jose
M. Sc Biostatistics, Department of
Biostatistics, Sunrise Hospital,
Kakkanad, Kochi, India

Correspondence
Nijith O Govindan
MS-Ortho, Orthopedic Surgeon,
Department of Orthopedics,
Sunrise Hospital, Kakkanad,
Kochi, India

A study on core cut biopsy in bone lesions

Nijith O Govindan, Jyothi Prasanth, Gopakumar TS, Akhil R Nambiar, Manjunath DS, Prathap Kumar, Biju M Nair and Christeena Jose

DOI: <http://dx.doi.org/10.22271/ortho.2017.v3.i1a.03>

Abstract

To study the histopathology of bone lesion received as core cut biopsy and the adequacy of core cut biopsy in diagnosis of bone lesion. Between June 2012 to May 2013, 90 core cut bone biopsy for histopathology were included in this study. Clinical and radiological findings were obtained from patient records. Core cut biopsy for suspected lesions were obtained by trephine biopsy needle and formalin fixed. Not more than two cores were taken. Except in young all biopsy was under local anesthesia. Deep seated lesions were sampled under CT guidance. Specimens were decalcified, paraffin embedded, haematoxylin, eosin stained and studied. All age group were included, youngest being one year and oldest being 92 year old. Males were 55% and females were 45%. 80% of bone biopsies could be diagnosed in closed biopsy specimens. 20% were inconclusive needed open surgical biopsy. Out of 80% diagnosed cases only 44% went for open surgical biopsy. In 92% (out of 44%) the diagnosis matched the core cut biopsy. The remaining cases which were not operated either were mainly metastasis or tuberculosis which was treated conservatively. Some were lost to follow up as some were referred to oncology centres for limb salvage options. Core cut bone biopsy is a convenient and cost effective method for diagnosis of bone lesions. It can be done for early diagnosis of bone lesions. It needs a closed association between the orthopaedician, radiologist and pathologist.

Keywords: Core cut biopsy, bone lesion, musculoskeletal tumors

1. Introduction

Early diagnosis and treatment is the key to success in all lesions of the bone. Biopsy can be done by fine needle aspiration, core needle biopsy or an open incisional biopsy. Complications are greater with incisional biopsy however this procedure is least likely to be associated with a sampling error and it provides the most tissue for additional diagnostics studies such as cytogenetics and flow cytometry. Difficulty with open incisional biopsy includes the necessity of operating room set up, general anesthesia, spinal or regional anesthesia. Morbidity of surgical site, surgical complication and tumor contamination are anticipated with open incisional biopsy. Finally expense is more when compared to fine needle aspiration and core cut biopsy. Tumor contamination is an important issue as far as future limb salvage is concern. In experienced hands core needle biopsy can provide an accurate diagnosis in 90% cases the limited amount of tissue may not be adequate for accurate grading or for additional studies. Fine needle aspiration may be 90% accurate for determining malignancy, however its accuracy to determine specific tumor type is low. The absence of malignant cells on fine needle aspiration is less reassuring than a negative incisional biopsy. Diagnostic accuracy greatly influenced by specimen obtained with various biopsy methods. Needle core biopsy and fine needle aspiration biopsy are less invasive, fewer complication and less expensive, the main disadvantage includes limited sample and small tissue core.

Open incision biopsy is considered gold standard for musculoskeletal lesions, which provides adequate tissue for histologic and additional studies. In present years the diagnostic accuracy of core biopsy or fine needle biopsy has been repeated to be close to that of open biopsy [1-6].

The use of needle biopsy replaced open biopsy for soft tissue mass in clinical musculoskeletal oncology [7]. Our study says core cut biopsy in bone lesions is also a promising diagnostic technique, as far as early diagnosis and cost effectiveness is concern.

2. Materials and methods

In this study 90 core cut percutaneous bone biopsies for histopathological assessment were done from June 2012 to May 2013. Clinical and imaging findings were obtained from patient records. All the core biopsies from the suspected lesions were obtained by trephine needle and fixed with formalin. Maximum 2 cores were taken. Except in very young age all biopsies were done under local anesthesia. Some lesions from the spine and deep seated regions were sampled under CT guidance [Fig 1]. All the samples were decalcified, paraffin embedded, Haematoxylin and Eosin stained and were studied. Cores excluded are core cut biopsies of soft tissues lesions without a bony component radiologically and Trephine biopsies taken as part of hematological workup.

3. Results

Total core cut biopsies during the study period was 90. All age groups patients were included in this study youngest being 1 year old and oldest being 92 years old. 55% were males and 45% were females. Most common site of distribution is spine include is 30% then femur 27% and the least being clavicle

and ulna 1.7% each [Table 1]. 52% are pathologically malignant, 20% inflammatory, 20% were inconclusive and about 8% were benign lesions [Table 2]. About 45% of inflammatory lesions were chronic inflammation, 25% Tuberculosis and about 20% were GCT [Table 3].

Among the malignant lesions poorly differentiated carcinoma metastasis were of maximum number 26%, this is followed by plasmacytoma 23%. The least are squamous cell carcinoma metastasis, langerhan cells histiocytosis and poorly differentiated malignancies [Table 4].

In this study 80% of bone biopsy could be diagnosed in closed biopsy specimens. 20% were inconclusive needed open surgical biopsy. Inconclusive materials were callus and necrotic material and degenerating bone. Out of 80% diagnosed cases only 44% went for open surgical biopsy. Out of 44%, 92% the diagnosis matched the core cut biopsy. The remaining cases which were not operated either were mainly metastasis or tuberculosis which was treated conservatively. Some were lost to follow up and some were referred to oncology centres for limb salvage options after diagnosis of malignant lesions by core cut biopsy.

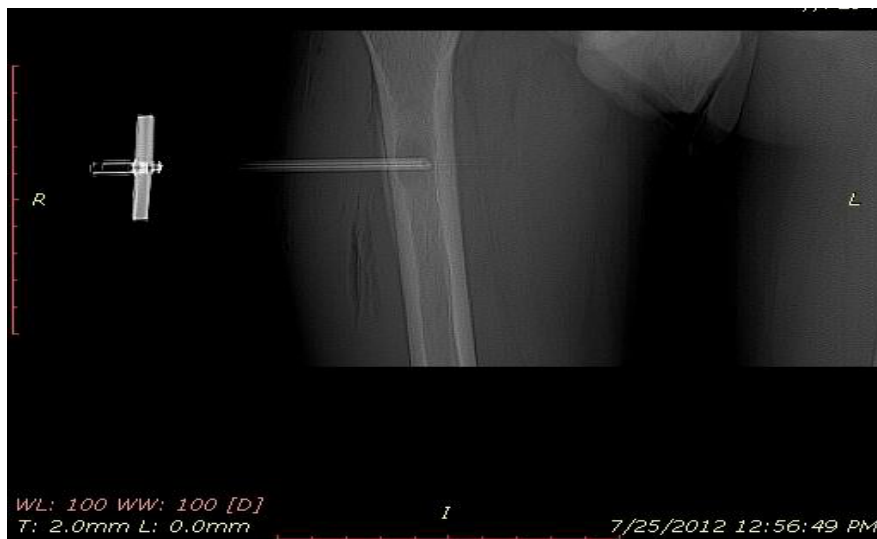

Fig 1: CT picture showing the trephine needle in situ.

Few cases in our study

1) A 44 year old gentleman presented with compression fracture of thoracic spine.

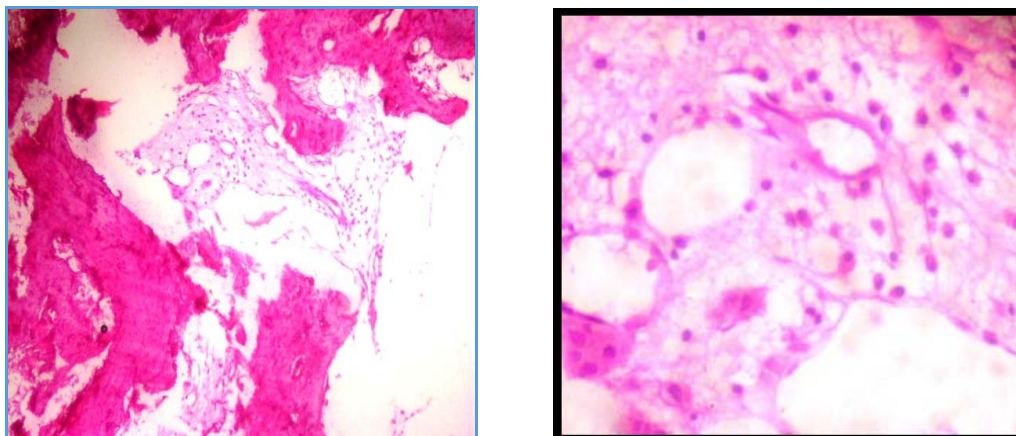


Fig 2-3: A CT guided biopsy showed sheets of plasma cells, favouring plasmacytoma.

2) A 60 year old male with lytic lesion of femur.

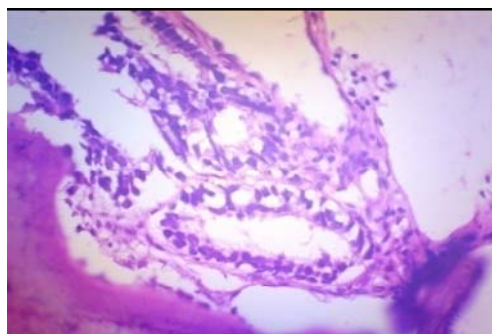
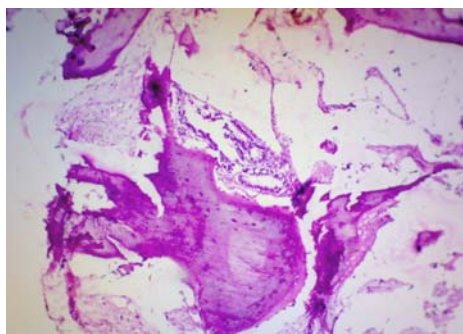


Fig 4-5: Biopsy showed malignant glands in between necrotic bony spicules, hence diagnosed as adeno carcinoma. A search for primary showed raised PSA and prostatic acinar adenocarcinoma.

3) A 12 year old boy presented with pain in right knee.

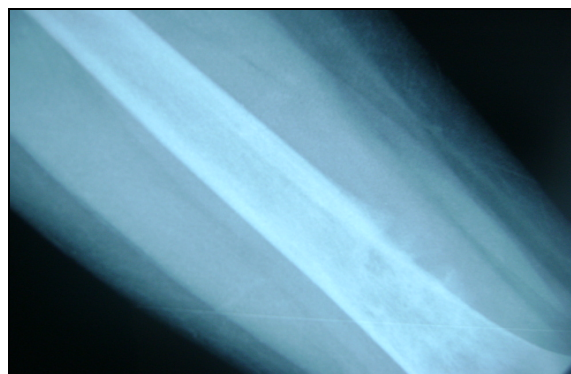


Fig 6: The X ray showed lesion in lower end of femur forming classical Codman triangle.

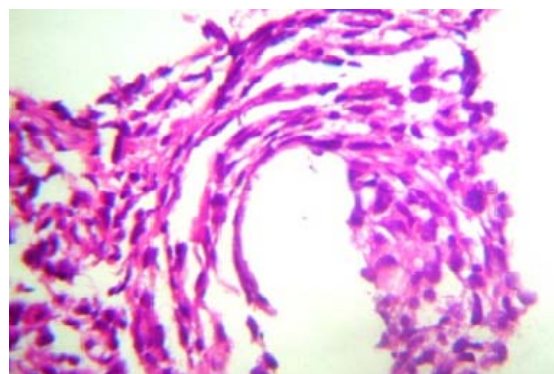


Fig 7: Biopsy showed malignant spindle cells, necrotic bone and few osteoid like material, hence diagnosed as osteosarcoma.

Table 1: Site distribution

Site	Percentage (%)
Spine	30
Femur	27
Tibia	16.6
Ilium	11
Humerus	7.7
Fibula	4.3
Clavicle	1.7
Ulna	1.7

Table 2: Pathology of lesions

Pathology of lesions	Percentage (%)
Malignancies	52
Inflammatory lesions	20
Inconclusive	20
Benign tumors	8

Table 3: The distribution of inflammatory lesions and benign tumors

Inflammatory lesions	Percentage (%)
Chronic inflammation	45
Tuberculosis	25
GCT	20
Cartilagenous lesions	10

Table 4: Distribution in Malignant lesions

Malignant lesions	Percentage (%)
Plasmacytoma	23
Round cell neoplasm	10.8
Osteosarcoma	10.8

Langerhan cell histiocytosis	6.8
Poorly diff carcinoma mets	26
Adenocarcinoma mets	12.9
Poorly diff malignancy	6.5
Sq.cell ca mets	3.2

4. Discussion

Percutaneous needle biopsy of suspected primary bone neoplasm is a well-established procedure in specialist centres, with a reported accuracy in diagnosis ranging from 78% to 97% [8, 9, 10]. It may be carried out as a closed percutaneous procedure by an orthopedic surgeon or a radiologist [11, 12]. A biopsy which has been inadequately obtained remains the commonest cause for inability to perform limb-salvage surgery [13]. Skrzynski *et al* obtained a diagnostic accuracy of 84% in outpatients with soft-tissue lesions or bone tumors with a palpable extra osseous mass [14]. The major shortcomings with core cut biopsies are that tissue may be either mainly necrotic or from a low-grade area of a lesion. A team approach of the orthopedic oncologist, pathologist and radiologist can make the results of percutaneous biopsy extremely effective and accurate [15] as it has been demonstrated in various studies [16, 17, 18]. Diagnostic yield increased with number of specimens obtained and it reached a plateau at three specimens for bone lesions [19]. Sclerotic lesions often require a cutting needle or drill to breach the cortex or reactive bone, and these samples can be macerated by crush artifacts. This hampers histological evaluation and thereby lowering diagnostic accuracy [20]. Frozen section at the time of biopsy may improve diagnostic accuracy. Diagnostic difficulty was associated with infections, and tumors located in the para spinal region [21].

Study shows that biopsy track from fine needle aspiration (22-25-gauge needles) have lesser risk of tumor contamination [22]. But the accuracy of fine needle aspiration biopsy is less than core cut bone biopsy [23, 24]. Tumor seeding is high with core cut biopsy especially in deep seated lesions [25, 26]. In this situation, image guided biopsy helps to overcome tumor seeding. Image guided needle biopsy accurate as open biopsy for the diagnosis and staging of musculoskeletal tumor but with fewer complications and low costs [27, 28].

In our study the most common site of lesion is spine followed by proximal femur. Both this sites core cut bone biopsy was undertaken with image assistance.

5. Conclusion

In this study, 80% of bone biopsies could be diagnosed in closed biopsy specimens. More than half the diagnosed cases were malignancies, majority being metastasis from poorly differentiated carcinoma, followed by plasmacytoma. Clinical history and radiological correlation is necessary to reach at a definitive diagnosis. Inconclusive cases were due to degenerating bone, fracture callus and inappropriate sampling. In Tuberculosis and chronic infections, a definitive diagnosis can be reached, where therapy can be directed accordingly. In disseminated malignancy, palliative care can be ensued. In Osteosarcoma, limb salvage surgery can be advised. Core cut bone biopsy, is convenient and cost effective method. It can be done for tissue diagnosis and helps in further management at the earliest in majority of cases. It needs a close association between the orthopedician, radiologist and pathologist.

6. References

1. Issakov J, Flusser G, Kollender Y, Merimsky O, Lifschitz-Mercer B, Meller I. Computed tomography-guided core needle biopsy for bone and soft tissue tumors. *Isr Med Assoc J.* 2003; 5:28-30.
2. Kilpatrick SE, Cappellari JO, Bos GD, Gold SH, Ward WG. Is fine-needle aspiration biopsy a practical alternative to open biopsy for the primary diagnosis of sarcoma? Experience with 140 patients. *Am J Clin Pathol.* 2001; 115:59-68.
3. Nagira K, Yamamoto T, Akisue T *et al.* Reliability of fine-needle aspiration biopsy in the initial diagnosis of soft-tissue lesions. *Diagn Cytopathol.* 2002; 27:354-361.
4. Madhavan VP, Smile SR, Chandra SS, Ratnakar C. Value of core needle biopsy in the diagnosis of soft tissue tumours. *Indian J Pathol Microbiol.* 2002; 45:165-168.
5. Torriani M, Etchebehere M, Amstalden E. Sonographically guided core needle biopsy of bone and soft tissue tumors. *J Ultrasound Med.* 2002; 21:275-281.
6. Nagira K, Yamamoto T, Akisue T *et al.* Reliability of fine-needle aspiration biopsy in the initial diagnosis of soft-tissue lesions. *Diagn Cytopathol.* 2002; 27: 354-361.
7. Welker JA, Henshaw RM, Jelinek J, Shmookler BM, Malawer MM. The percutaneous needle biopsy is safe and recommended in the diagnosis of musculoskeletal masses. *Cancer.* 2000; 89:2677-2686.
8. Saifuddin A, Mitchell R, Burnett SJD, Sandison AJAS. Pringle Ultrasound-guided needle biopsy of primary bone tumours. *J Bone Joint Surg [Br].* 2000; 82-B:50-4. Received 27 April 1999; Accepted after revision 15 June 1999.
9. Ayala AG, Zornosa J. Primary bone tumors: percutaneous needle biopsy: radiologic-pathologic study of 222 biopsies. *Radiology.* 1983; 149:675-9.
10. Stoker DJ, Cobb JP, Pringle JAS. Needle biopsy of musculoskeletal lesions: a review of 208 procedures. *J Bone Joint Surg [Br].* 1991; 73-B:498-500.
11. Simon MA, Biermann JS. Biopsy of bone and soft-tissue lesions. *J Bone Joint Surg [Am].* 1993; 75-A:616-21.
12. Springfield DS, Rosenberg A. Editorial. Biopsy: complicated and risky. *J Bone Joint Surg [Am].* 1996; 78A:639-43.
13. Mankin HJ, Mankin CJ, Simon MA. The hazards of biopsy revisited. *J Bone Joint Surg [Am].* 1996; 78-A:656-63.
14. Skrzynski MC, Biermann JS, Montag A, Simon MA. Diagnostic accuracy and charge-savings of outpatient core needle biopsy compared with open biopsy of musculoskeletal tumours. *J Bone Joint Surg [Am].* 1996; 78-A:644-9.
15. James Jelinek S, Mark Murphey D, James Welker A, Robert Henshaw M, Mark Kransdorf J, Barry Shmookler M *et al.*, Diagnosis of Primary Bone Tumors with Image-guided Percutaneous Biopsy: Experience with 110 Tumors. *Radiology.* 2002, 731-37.
16. Ward WG, Kilpatrick S. Fine needle aspiration biopsy of primary bone tumors. *Clin Orthop.* 2000; 373:80-87.
17. Skrzynski C, Biermann JS, Montag A, Simon MA. Diagnostic accuracy and charge savings of outpatient core needle biopsy compared with open biopsy of musculoskeletal tumors. *J Bone Joint Surg Am.* 1996; 78:644-649.
18. Fraser-Hill MA, Renfrew DL, Hilsenrath PE. Percutaneous needle biopsy of musculoskeletal lesions. II. Cost-effectiveness. *AJR Am J Roentgenol.* 1992; 158:813-818
19. Jim Wu S, Jeffrey Goldsmith D, Perry Horwich J, Sanjay Shetty K, Mary Hochman G. Bone and Soft-Tissue Lesions: What Factors Affect Diagnostic Yield of Image-guided Core-Needle Biopsy? *Radiology.* 2008; 248:3.
20. McCarthy EF. CT-guided needle biopsies of bone and soft tissue tumors: a pathologist's perspective. *Skeletal Radiol* 2007; 36:181-182.
21. Bruce Rougraff T, Albert Aboulafia, Sybil Biermann J, John Healey. Biopsy of Soft Tissue Masses Evidence-based Medicine for the Musculoskeletal Tumor Society. *Clin Orthop Relat Res.* 2009; 467:2783-2791.
22. Kilpatrick SE, Cappellari JO, Bos GD, Gold SH, Ward WG. Is fine-needle aspiration biopsy a practical alternative to open biopsy for the primary diagnosis of sarcoma? Experience with 140 patients. *Am J Clin Pathol.* 2001; 115(1):59-68.
23. Kosciak RL, Petersilge CA, Makley JT, AbdulKarim FW. CT-guided fine needle aspiration and needle core biopsy of skeletal lesions: complementary diagnostic techniques. *Acta Cytol.* 1998; 42(3):697-702.
24. Schweitzer ME, Gannon FH, Deely DM, O'Hara BJ, Juneja V. Percutaneous skeletal aspiration and core biopsy: complementary techniques. *AJR Am J Roentgenol.* 1996; 166(2):415-418.
25. Schwartz HS, Spengler DM. Needle tract recurrences after closed biopsy for sarcoma: three cases and review of the literature. *Ann Surg Oncol.* 1997; 4(3):228-236.
26. Davies NM, Livesley PJ, Cannon SR. Recurrence of an osteosarcoma in a needle biopsy track. *J Bone Joint Surg Br.* 1993; 75(6):977-978.
27. De Santos LA, Murray JA, Ayala AG. The value of percutaneous needle biopsy in the management of primary tumors. *Cancer.* 1979; 43(2):735-744.
28. Skrzynski MC, Biermann JS, Montag A, Simon MA. Diagnostic accuracy and charge-savings of outpatient core

needle biopsy compared with open biopsy of musculoskeletal tumors. J Bone Joint Surg Am. 1996; 78(5):644-649.